

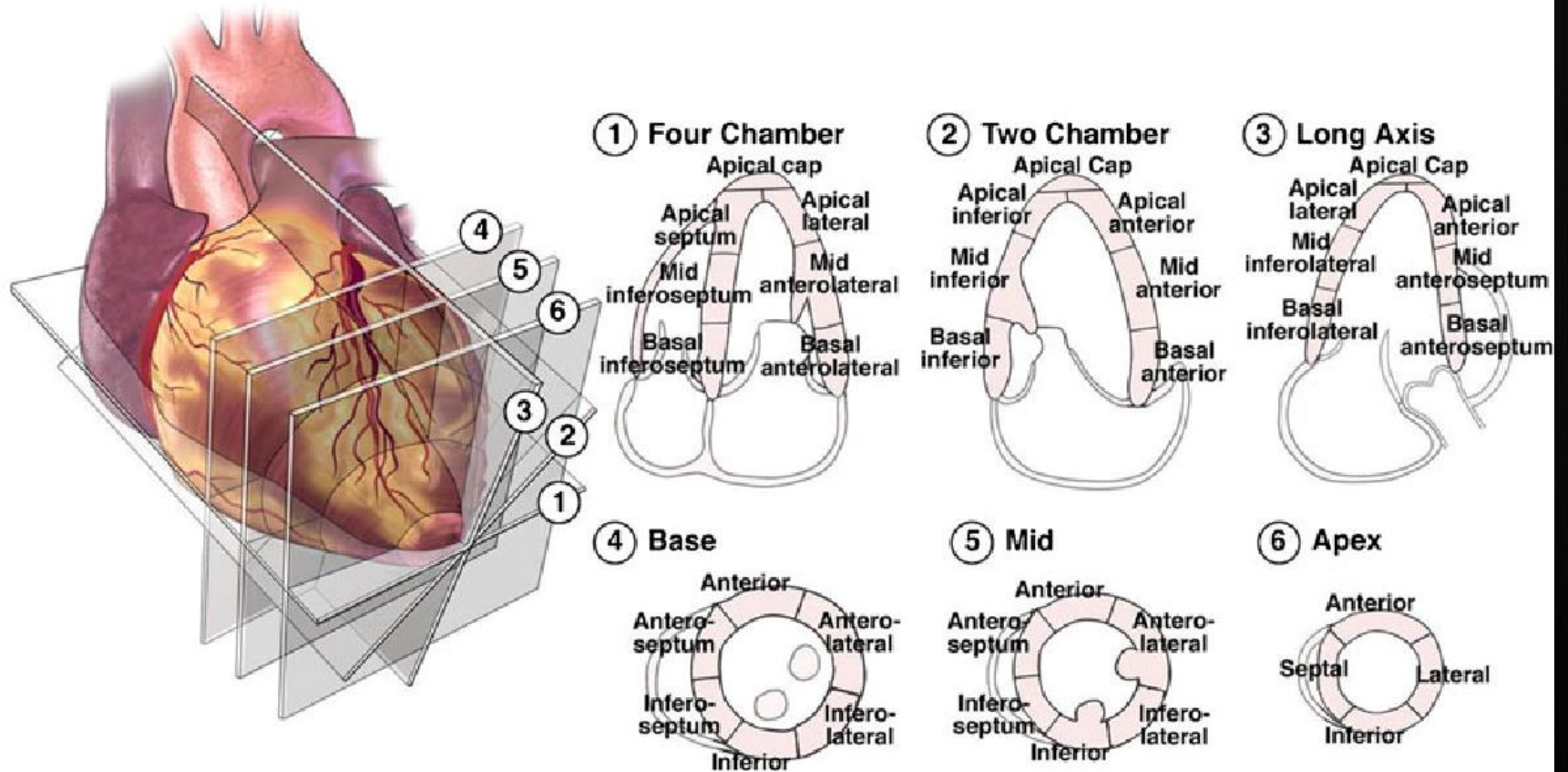
Wall motion

- **Hyperkinetic or hyperkinesia**
 - increased wall thickening
 - systolic inward excursion
- **Normokinetic or normokinesia**
 - normal wall thickening
 - normal systolic inward excursion
- **Hypokinetic (mild/severe) or hypokinesia**
 - reduced wall thickening
 - reduced systolic inward excursion
- **Akinetic or akinesia**
 - absent wall thickening
 - reduced or absent systolic excursion
- **Dyskinetic or dyskinesia**
 - absent wall thickening
 - systolic outward excursion or lengthening

Further cardiac wall motion abnormalities

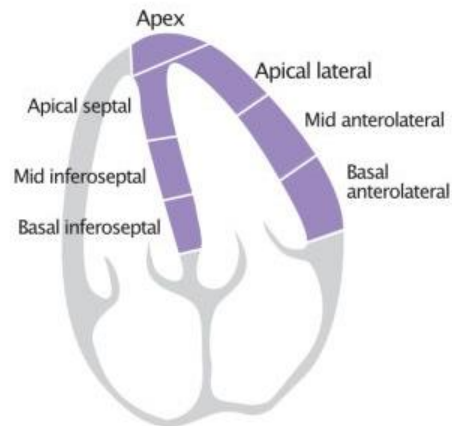
- **Tardokinesis:** delayed excursion and thickening or post-systolic shortening
- **Paradoxical septal motion:** type of dyskinesia where the septum is moving away from the left ventricular free wall during systole

Chamber views

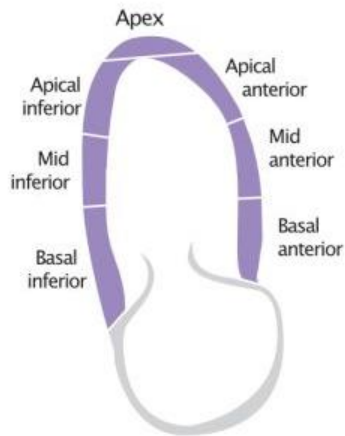


Chamber views

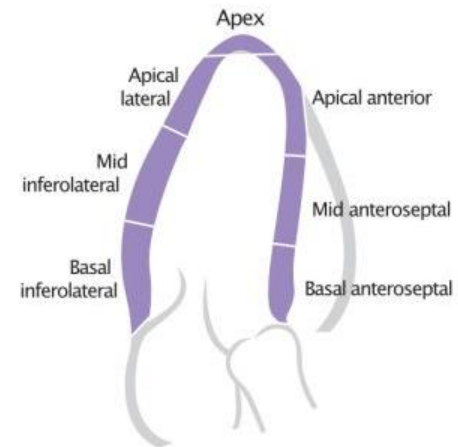
Apical 4-chamber view (A4C)



Apical 2-chamber view (A2C)



Parasternal long-axis view (PLAX)



Parasternal short-axis view (PSAX)

